





1. Wound characteristics

In order to provide effective wound management a thorough understanding of the wound characteristics is important. The wound characteristics will help to guide the most appropriate wound debridement, type of dressings and offloading devices to be used for a wound.

The wound base (bed) can have one type of tissue or can be made up of many types of tissues. It is important to consider each of the tissue types that make up the wound.

Figure 1: Characteristics of wound base

Tissue type:	Description	
Epithelial tissue	<ul style="list-style-type: none"> • Pink, recently healed skin • This tissue is still fragile and at risk of further injury. The area should be offloaded, monitored and protected to prevent the wound breaking down again. 	
Granulation tissue	<ul style="list-style-type: none"> • New cell growth from the base of the wound, tissue is a red colour. • This tissue should be offloaded and protected for continued healing. 	
Slough	<ul style="list-style-type: none"> • Dead tissue that has separated from the living tissue, usually yellow in colour. • Slough will inhibit and delay healing - should be removed from a wound wherever possible to promote healing. • The tissue underneath should be offloaded and protected for continued healing. 	
Necrotic tissue	<ul style="list-style-type: none"> • Dead or dying tissue that is a black or brown colour. • Is often a sign of ischemia (poor blood supply). • Do not attempt debridement if vascular insufficiency suspected. 	

1.1 Wound exudate

Exudate is the fluid that comes out of a wound. The amount of exudate will affect how moist the wound and surrounding tissues are. Exudate can be described by the amount and type present. Too much exudate can cause a wound and surrounding tissues to become very wet, making the wound worse.

Figure 2: Wound exudate description

		Description
Exudate amount ^{1, 2} :	None	<ul style="list-style-type: none"> Wound base and dressings are dry
	Low	<ul style="list-style-type: none"> Wound tissues are moist; small amount in dressing
	Medium	<ul style="list-style-type: none"> Wound tissues are wet; dressing is wet, but fluid is contained within it
	High	<ul style="list-style-type: none"> Wound tissues are filled with fluid; fluid extends out of dressing onto wrap or clothes.
Exudate type ³ :	Clear (Serous)	<ul style="list-style-type: none"> Thin, clear and watery fluid
	Clear with blood (Serosanguineous)	<ul style="list-style-type: none"> Thin, watery, pale red or pink fluid
	Thick yellow (purulent)	<ul style="list-style-type: none"> Thick, cloudy drainage that is tan, yellow, green, or brown Purulent exudate is never normal and is often associated with infection or high bacteria levels, a Doctor should review the wound immediately
	Thick yellow (purulent) with blood	<ul style="list-style-type: none"> Thick yellow (purulent) with signs of blood. Purulent exudate is never normal and is often associated with infection or high bacteria levels, a Doctor should review the wound immediately

¹ Morgan, N., *How to assess wound exudate*. Best of the Best, 2015. 4(5).



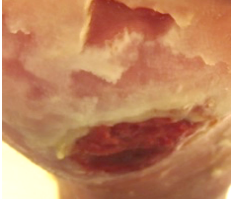
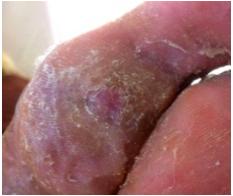
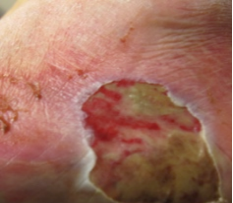
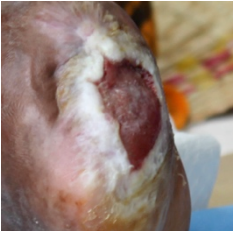
² DeMarco, S. *Wound and Pressure Ulcer Management*. John Hopkins Medicine [cited 2017 16th June]; Available from: http://www.hopkinsmedicine.org/gec/series/wound_care.html.

³ Morgan, N., *How to assess wound exudate*. Best of the Best, 2015. 4(5).

5.2 Wound surrounding skin

The condition of the surrounding tissue is important to consider when choosing the type of wound management and dressings. Protecting the surrounding skin is important to prevent new wound development or other problems.

Figure 3: Condition of surrounding skin

Wound base tissue type:	Description
Normal	<p>Skin looks the same as healthy skin on the rest of the foot.</p> 
Callus	<p>Hard, thick skin. Can cause added pressure to underlying tissue and may cover / hide underlying wounds.</p> 
Fragile	<p>Thin skin that can easily tear.</p> 
Dry	<p>Skin that is dry and cracked.</p> 
Rash	<p>Skin that is coloured, bumpy, dry, blistered or swollen. Usually has a definite edge that matches with a dressing or tape that was used.</p> 
Macerated (moist)	<p>Occurs when too much moisture is trapped against the skin. The skin will turn white or grey and will soften and wrinkle.</p> 
Swollen	<p>Swelling of the surrounding skin can be a combined with an increase of temperature; redness and exudate could be a sign of infection.</p> 